

Production of Bleomycin-induced pulmonary fibrosis model mice by oropharyngeal aspiration and evaluation of the efficacy of Nintedanib

○ Nahoko Matsuki, Naomi Hikawa, Kousuke Morizumi, Seiichi Katayama, Katsuhide Nishi, Naoyuki Hironaka

Objective

Idiopathic Pulmonary Fibrosis (IPF) is a progressive disease that causes loss of respiratory function by fibrosis. Two anti-fibrotic drugs are available in Japan, but these are not much effective.

Bleomycin, an anticancer drug, causes pulmonary fibrosis as a side-effect. In the present study, IPF model mice are induced by administration of bleomycin. Nintedanib is one of the IPF drugs. It inhibits growth and migration of fibroblasts by binding fibroblast growth factor receptor, platelet derived growth factor receptor, and vascular endothelial growth factor receptor. In the present study, we evaluated the efficacy of Nintedanib in the IPF model.

Summary in Japanese

特発性肺線維症 (IPF) は、肺の間質に線維化が生じて呼吸不全となる疾患であり、現在有用な治療薬はない。ニンテダニブは、線維芽細胞の活性化を抑制することで作用する抗線維化薬として知られている。そこで、我々は、肺線維症を引き起こすブレオマイシン (BLM) を使用し、口腔咽頭吸引法 (OPA) にてマウスの肺にBLM (1.5 mg/kg) を投与することでIPFモデルを作製し、ニンテダニブの薬効を評価した。ニンテダニブは30, 60, 120 mg/kgの用量を1日1回の頻度で22日間経口投与した。評価項目はμCT解析、肺中ヒドロキシプロリン量、病理組織学的検査、SpO₂、呼吸機能検査および気管支肺胞洗浄液 (BALF) 中サイトカインとした。ニンテダニブ群では、モデル群と比較して、μCT解析による低通気部位の減少および病理組織学的検査による線維化の減少が認められ、ニンテダニブの抗線維化作用を捉えることができた。

Materials and Methods

Animal

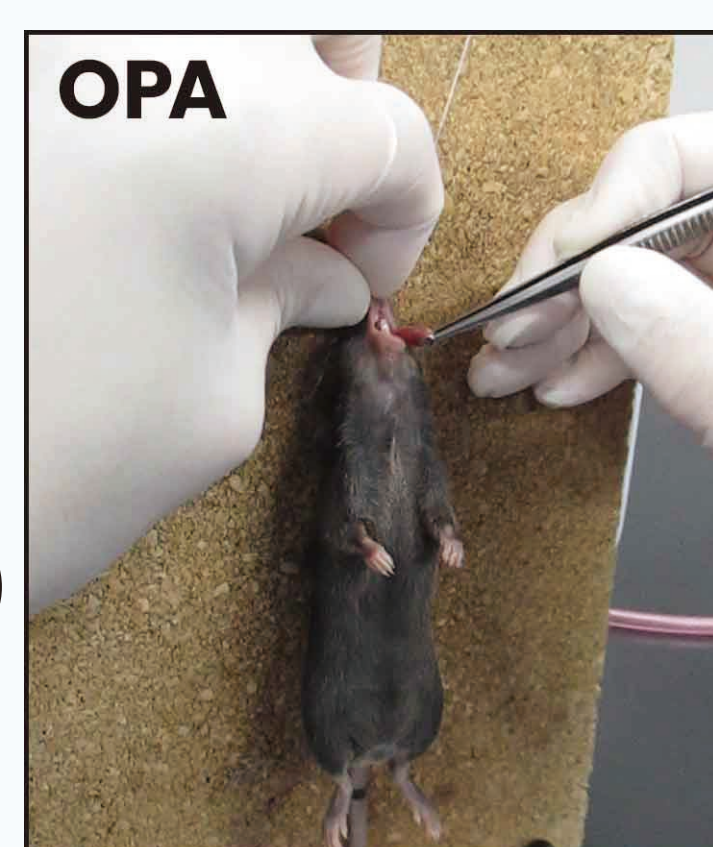C57BL/6N mice, Male, 10 weeks old

Reagents

Bleomycin hydrochloride (BLM), Nippon Kayaku Co., Ltd.
Nintedanib ethanesulfonate, Biosynth Ltd.

Preparation of IPF model: Oropharyngeal aspiration (OPA)

Bleomycin hydrochloride was administered to oropharynx at a dose of 1.5 mg/kg



Instruments

SpO₂ (Oxygen saturation):

Pulse oximeter for laboratory animals, MouseOX® Plus (STARR Life Sciences Corp.)

μCT (micro-Computed Tomography):

micro-X-ray CT for laboratory animals, CosmoScan GX II (Rigaku Corp.)

CT image analysis:

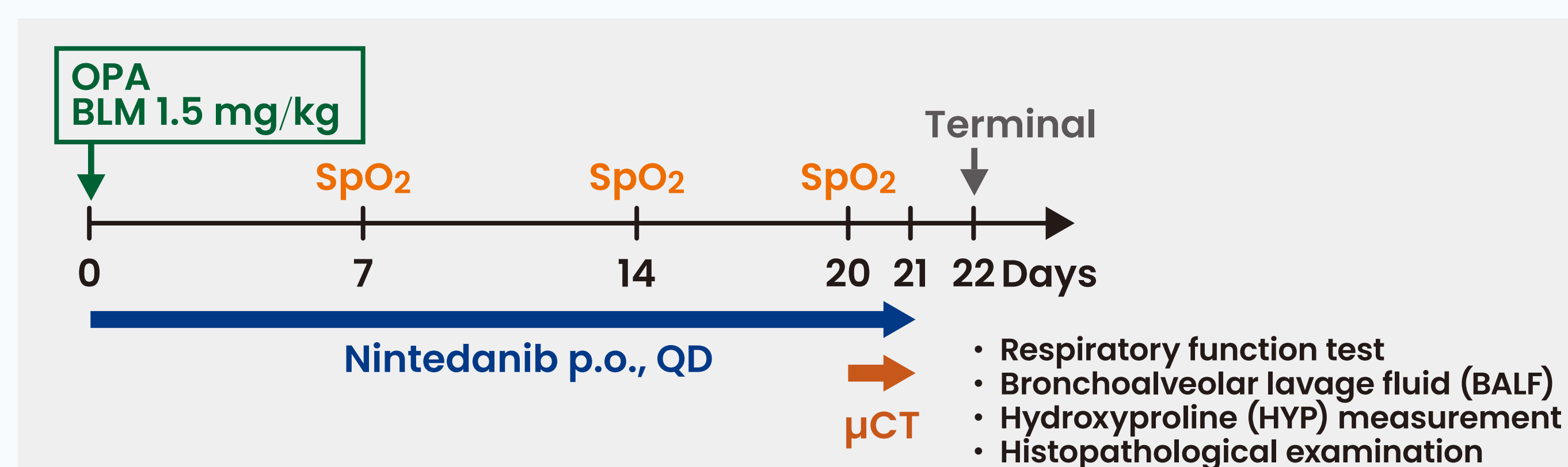
Analyze 14.0 software (AnalyzeDirect, Inc.)

Respiratory function test:

FinePointe™ Resistance & Compliance (Data Sciences International Inc.)

Test group	Number of animals	Left lung		Right lung
		BALF	Histopathological examination	HYP
Normal	10	5	5	10
Model	10	5	5	10
Nintedanib 30 mg/kg	10	5	5	10
Nintedanib 60 mg/kg	10	5	5	10
Nintedanib 120 mg/kg	10	5	5	10

Study schedule

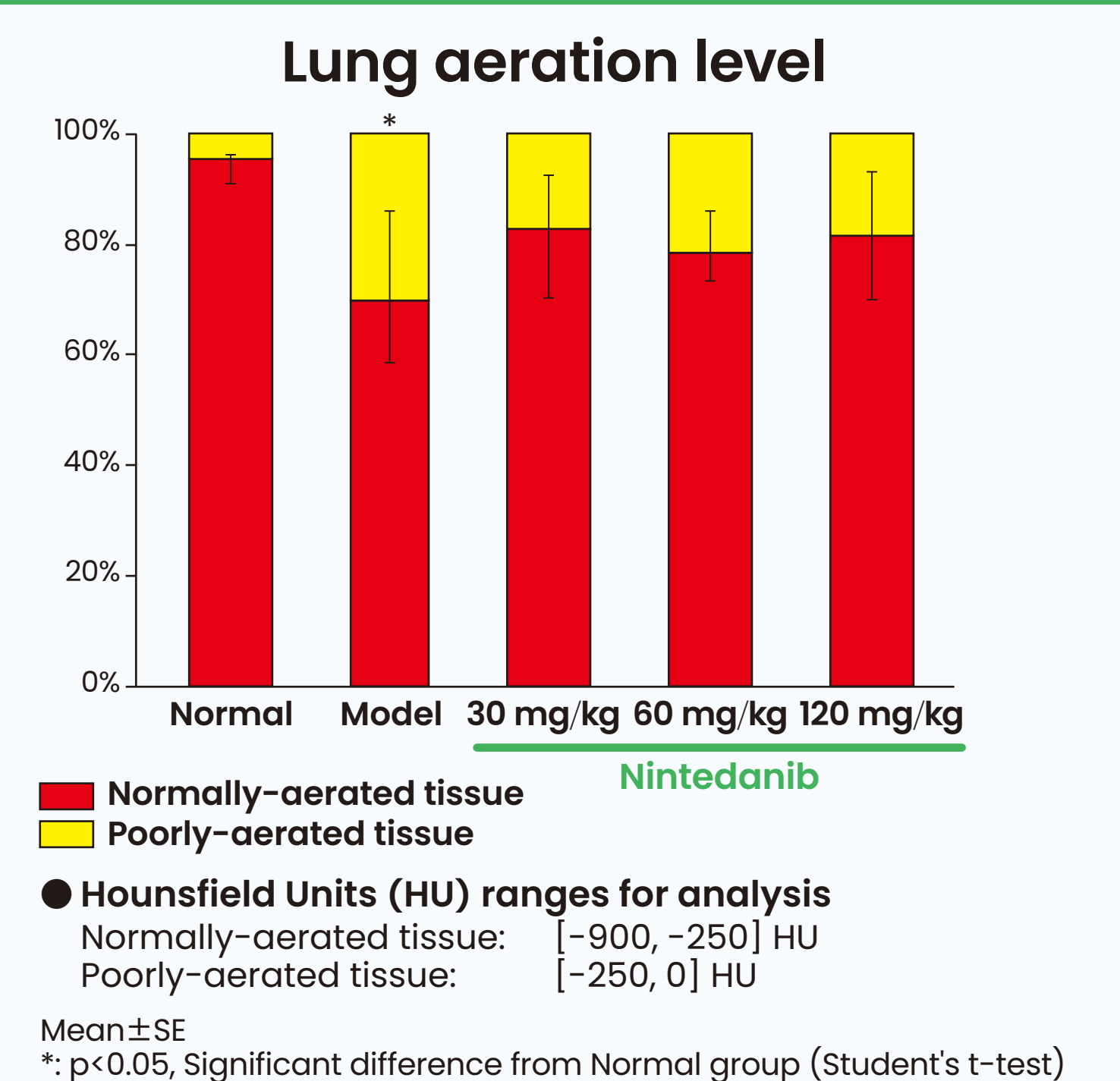
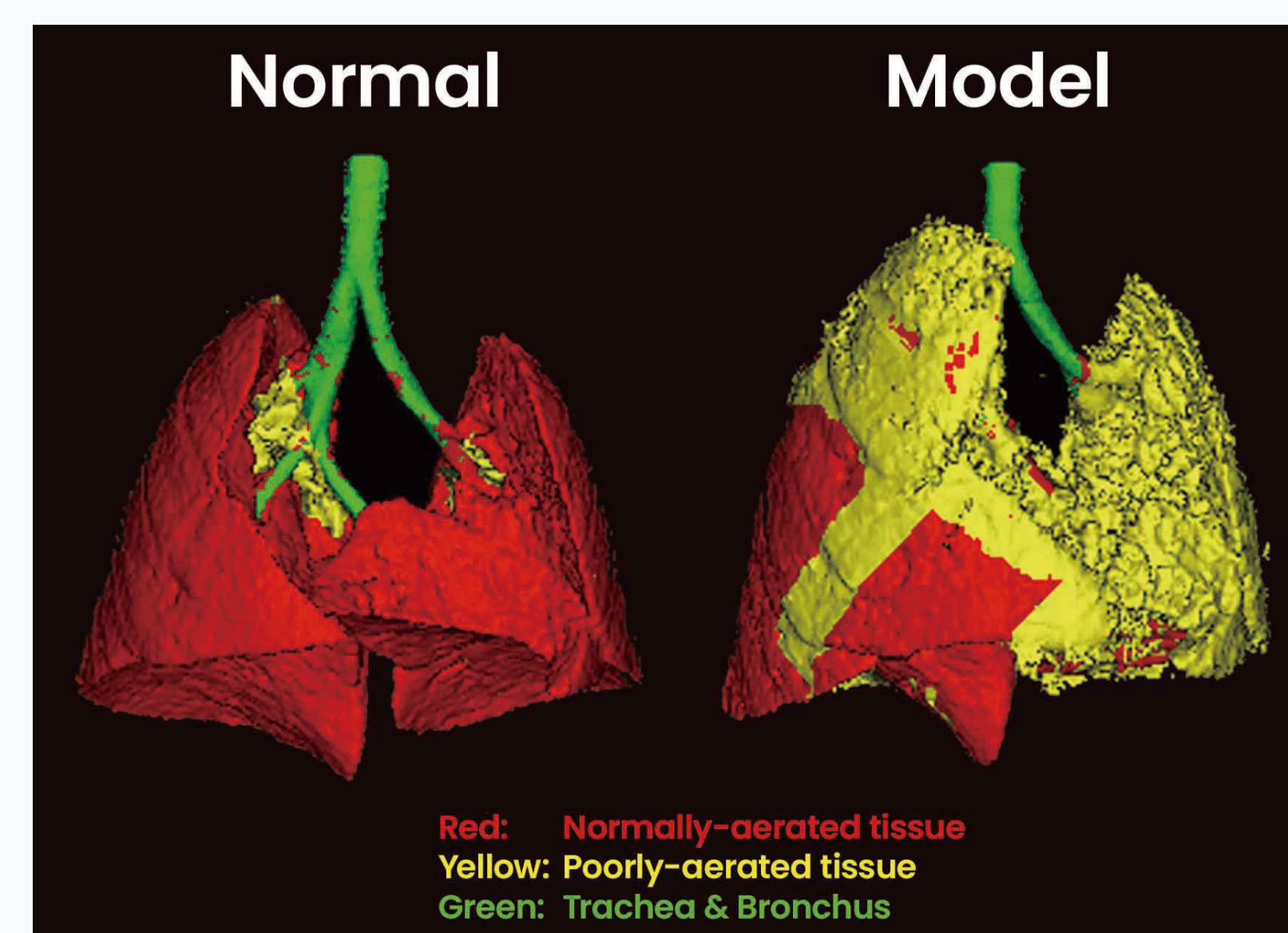


Conclusion

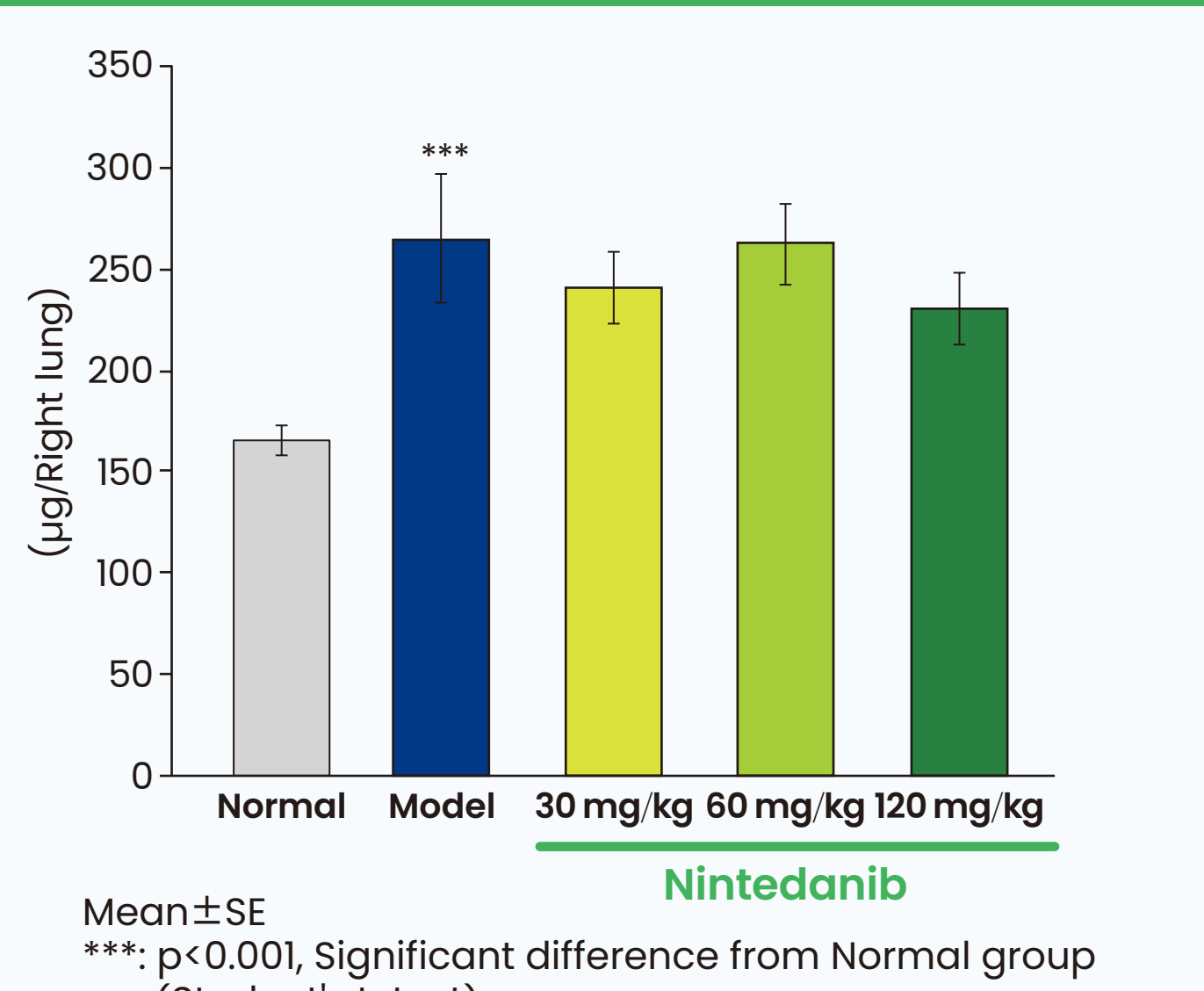
Histopathological examination showed that Nintedanib decreased fibrosis. CT image analysis revealed that the percentage of poorly-aerated tissue was decreased by 10 percent in the Nintedanib groups. In addition, SpO₂ level and the minute-volume in the Nintedanib 60, 120 mg/kg groups tended to be higher than those in the model group. In Nintedanib 60 mg/kg group, the levels of TGF-β1, IL-12p40, and Eotaxin in BALF were decreased by approximately 30 percent. Nintedanib was not much effective on the HYP level but it showed suppressive effects on fibrosis as revealed by histopathological examination and CT image analysis. In conclusion, Nintedanib could have anti-fibrotic effects on the IPF model.

Results

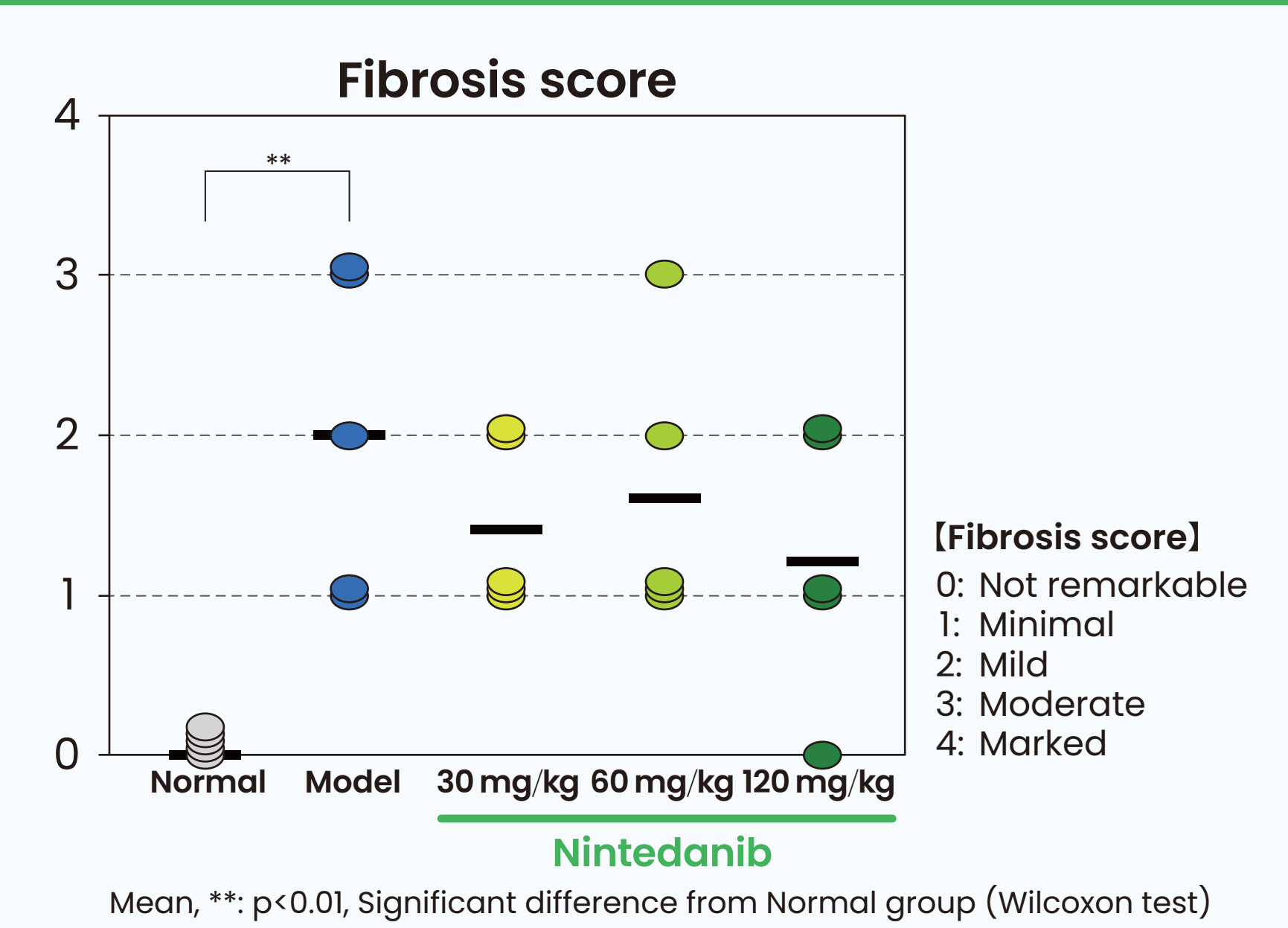
μCT analysis



Hydroxyproline

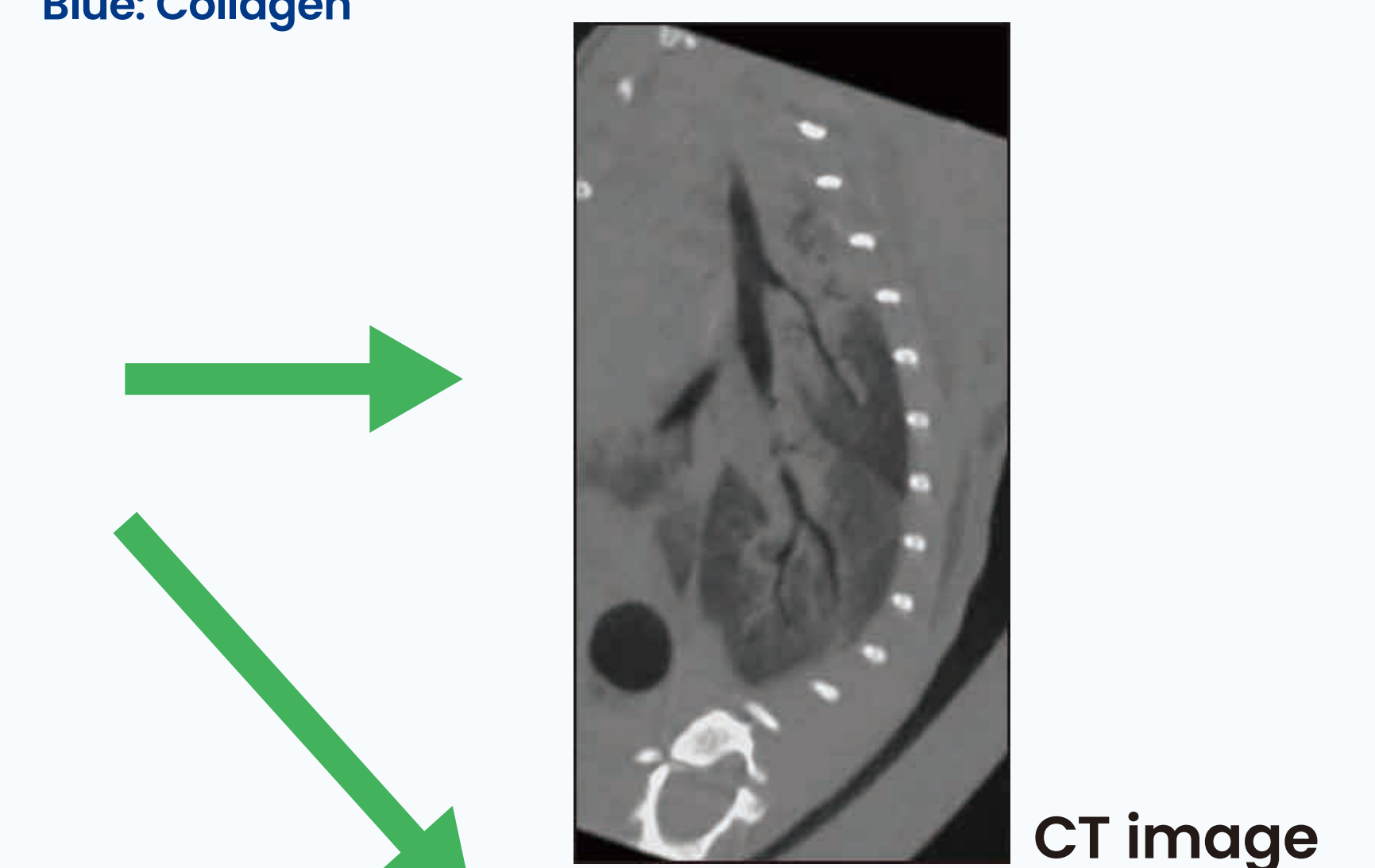
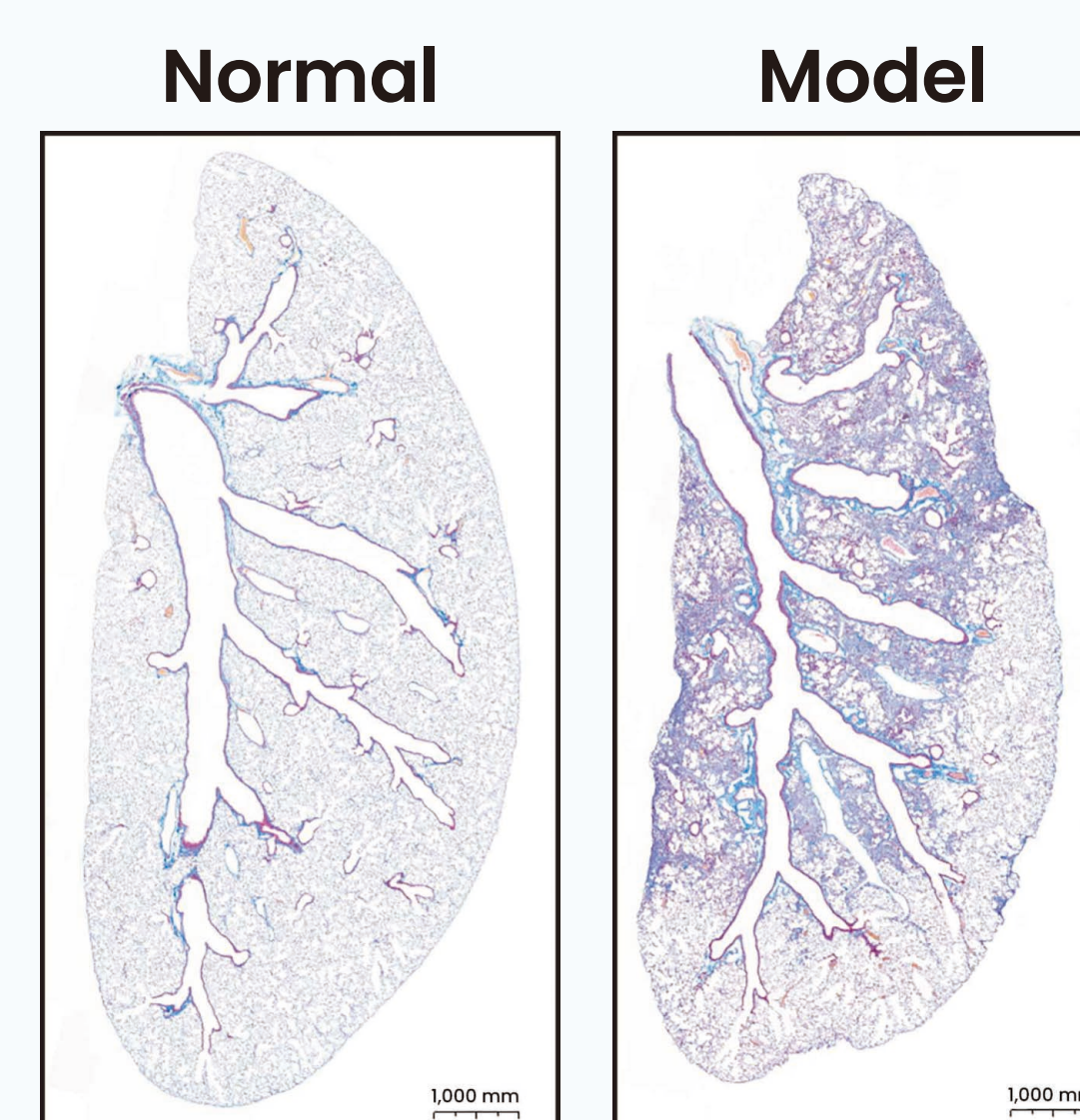


Histopathological examination

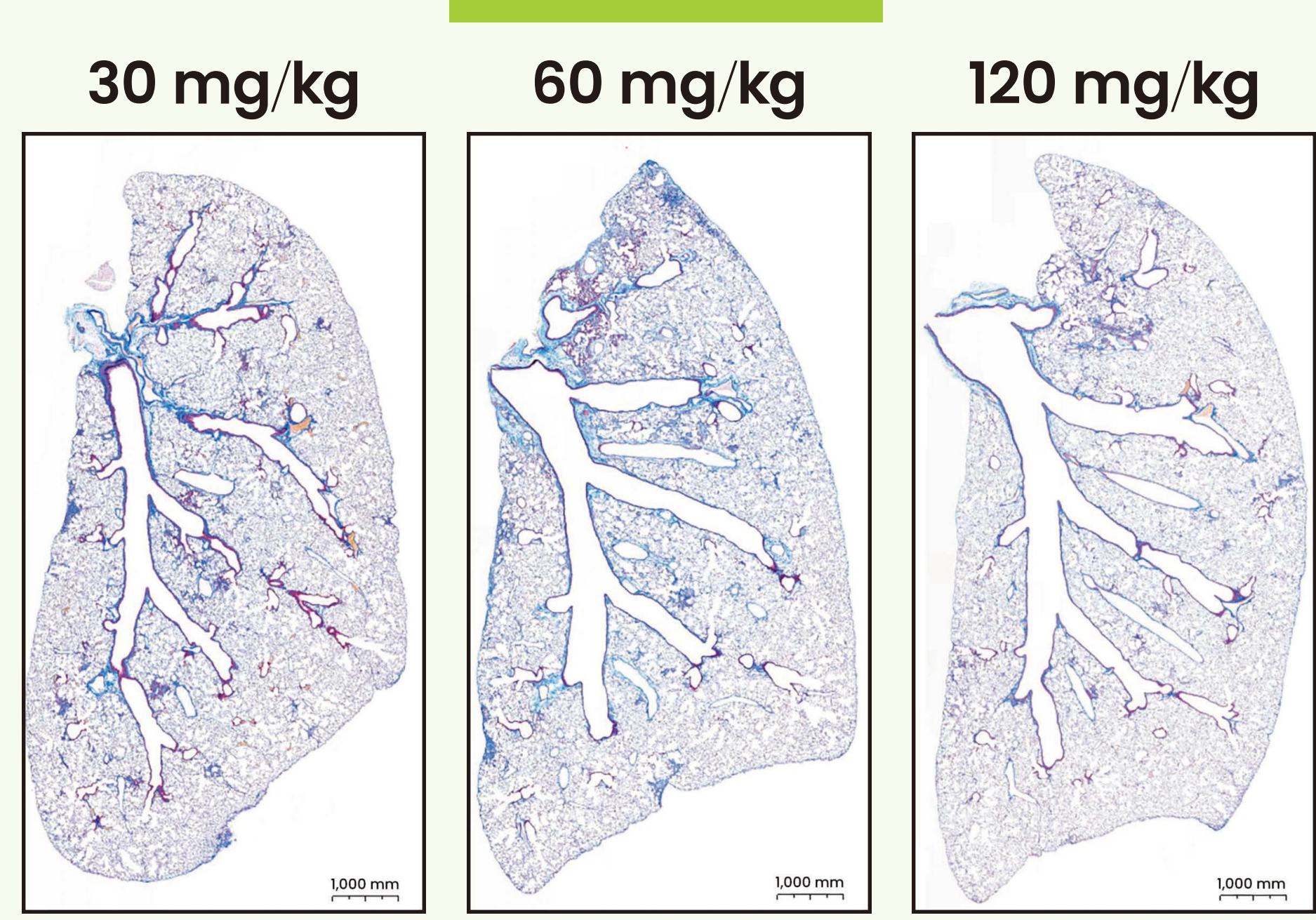


Masson Trichrome staining

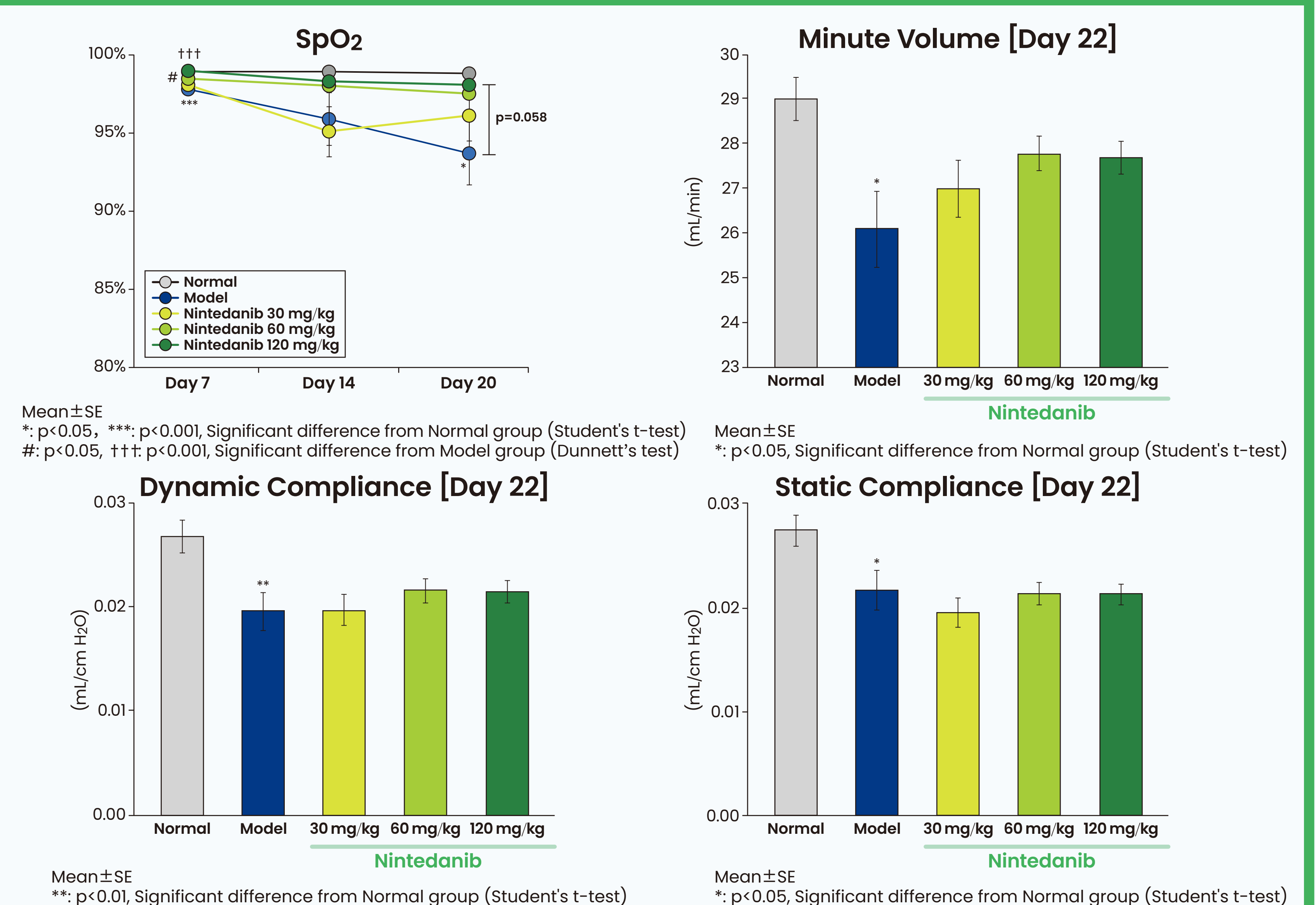
Blue: Collagen



Nintedanib



Respiratory function



Quantification of cytokines

