Mediford Corporation

Evaluation of Phototoxicity Using Pigmented Rats (Long-Evans): Comparison with Sprague-Dawley Rats

有色ラット（Long-Evans）を用いた光毒性評価の検討 - Sprague-Dawleyラットとの比較 –

○ Hitoshi Katou, Yuka Sasaki, Takashi Takano, Yutaka Nakahara, Jun Tsuchida, Naoki Aizawa, Haruka Moriyama, Tsuyoshi Higuchi

Research Unit II, Drug Discovery Innovation Center, Mediford Corporation

Objective

Sprague-Dawley (SD) rats are routinely used to evaluate the phototoxic potential of orally administered compounds and have shown sufficient sensitivity to phototoxicity regardless of melanin affinity. However, pigmented strains may be useful for evaluating compounds with melanin affinity. This study examined UV-induced phototoxic responses in Long-Evans (LE) rats and compared them with those in SD rats to assess the suitability of LE rats as a model for skin phototoxicity evaluation.

Materials and Methods

Animals
Female Crl:CD(SD) rats and Iar:Long-Evans (LE) rats, 7 weeks old

Test Article
8-Methoxypsoralen (8-MOP; Sigma-Aldrich Co. LLC)

Vehicle
0.5 w/v% aqueous methylcellulose solution

Route of Administration
Oral gavage

Dosing Regimen
Single administration or repeated administration for 4 consecutive days

Group Design
As shown in the table.

Group	Strain	Test Article	Dose (mg/kg)	UVA Irradiation Energy	Dosing Period (days)	No. of animals
I	LE	8-MOP	5	None	4	3
II	LE			10 J/cm²	1	5
III	LE			10 J/cm²	4	5
IV	SD			None	4	3
V	SD			10 J/cm²	1	5
VI	SD			10 J/cm²	4	5

UV Irradiation Method
Dorsal hair was removed using electric clippers to prepare the evaluation sites, consisting of UV-irradiated and non-irradiated areas.
In LE rats, pigmented areas were included in the evaluation sites.
Approximately 1 h after dosing, animals were restrained and exposed to UVA at 10 J/cm² for approximately 1 h. UV irradiation was performed using a DermaRay 200 device. A 3-mm-thick glass filter was attached to block wavelengths of 320 nm or shorter.

Endpoints

1) Skin Observation
- Time points: 2, 24, 48, and 72 h after UV irradiation
- Sites: UV-irradiated site, non-irradiated site, and auricular skin
- Items: Erythema/eschar formation and edema formation
- Scoring: Draize criteria (As shown in the table)

Score for erythema and eschar formation
0: No erythema
1: Very slight erythema (barely perceptible)
2: Well defined erythema
3: Moderate to severe erythema
4: Severe erythema (beet redness) to slight eschar formation (injuries in depth)

Score for edema formation
0: No edema
1: Very slight edema (barely perceptible)
2: Slight edema (edges of area well defined by definite raising)
3: Moderate edema (raised approximately 1 mm)
4: Severe edema (raised more than 1 mm and extending beyond area of exposure)

Assessment: dorsal skin, auricular skin, and pigmented/non-pigmented dorsal areas in LE rats
Mean score: calculated for each group at each time point
Mean score = (Erythema/eschar score + Edema score)/No. of animals

2) Ophthalmic Examination
Performed before dosing and after completion of the 72-h evaluation after UV irradiation.
Observation items: Pupillary light reflex, Anterior segment, Ocular media, Fundus

3) Ocular Histopathology
After ophthalmic examination, eyeballs were collected and processed for H&E staining and microscopic examination.

Protocol

▽ : Administration ▼ : UVA irradiation ▼ : Skin reaction assessment
▼ : Ophthalmic examination ▼ : Ocular tissue collection

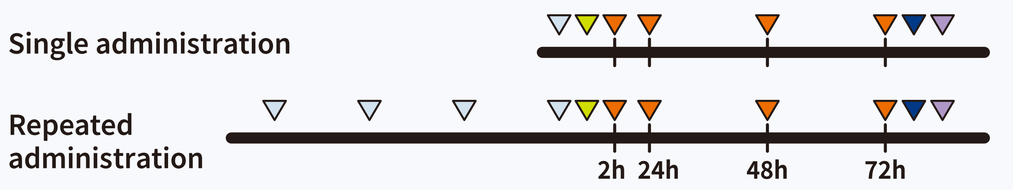

Discussion and Conclusion

The weaker auricular skin reactions and absence of retinal lesions in LE rats may be attributable, at least in part, to the protective effects of melanin pigmentation. Because the present evaluation was primarily intended to assess UV-induced skin phototoxicity, ocular findings were considered supportive rather than primary endpoints.

LE rats showed sufficient sensitivity for detecting UV-induced phototoxic responses in the skin, including the dorsal and auricular regions. These findings support the suitability of LE rats for skin phototoxicity evaluation, particularly when assessing compounds for which the use of pigmented animals may be relevant.

We thank to Asami Hanazawa (Central Institute for Experimental Medicine and Life Science) for providing experiment, and Atsushi Sugiyama (Toho University) for advising the poster presentation.

mediford
A Member of PHC Group

Results

Skin Score

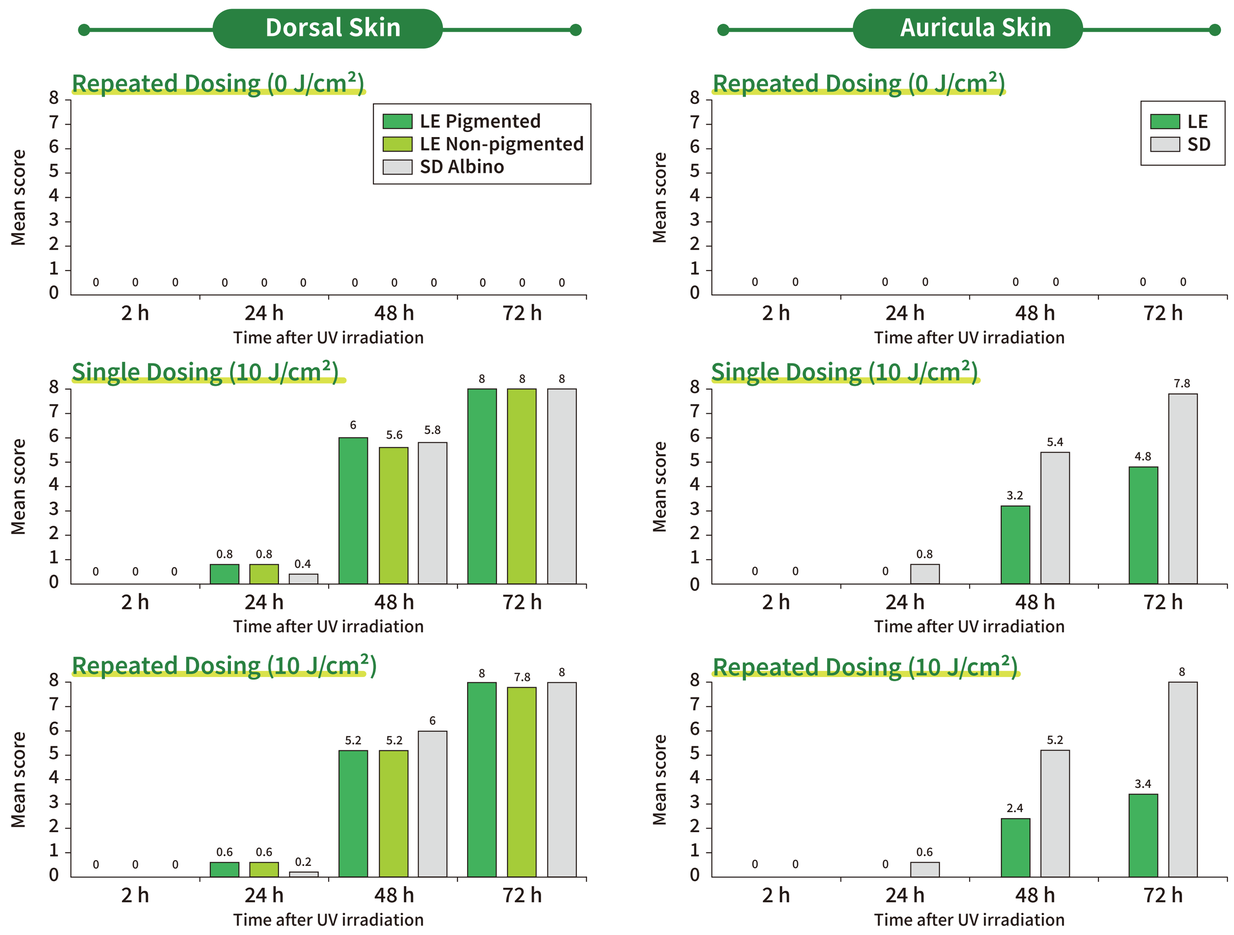

LE rats showed clear skin reactions at UV-irradiated sites of the auricular and dorsal skin after both single and repeated dosing. Compared with SD rats, dorsal skin reactions were comparable, whereas auricular skin reactions were slightly weaker in LE rats than in SD rats.

Ophthalmic Examination Findings at 72 h After UVA Irradiation

Group	Strain	Dosing Period	UVA	No. of animals	Findings (animals)		
					Pupillary light reflex	Anterior segment	Ocular media and Fundus
I	LE	Repeated	-	3	No change (3)	No change (3)	No change (3)
II	LE	Single	+	5	Not determined (2)	Corneal edema (5)	Not determined (5)
III	LE	Repeated	+	5	Not determined (1)	Corneal edema (5)	Not determined (5)
IV	SD	Repeated	-	3	No change (3)	No change (3)	No change (3)
V	SD	Single	+	5	Not determined (4)	Corneal edema (5), Iris synechia (5), Adhered substance on posterior capsule (2)	Not determined (5)
VI	SD	Repeated	+	5	Not determined (2)	Corneal edema (5), Iris synechia (5), Adhered substance on posterior capsule (3)	Not determined (5)

LE rats showed ophthalmic findings, including corneal edema. In SD rats, corneal edema and iridial adhesion were observed, and the changes tended to be slightly more severe than those in LE rats.

Ocular Histopathology

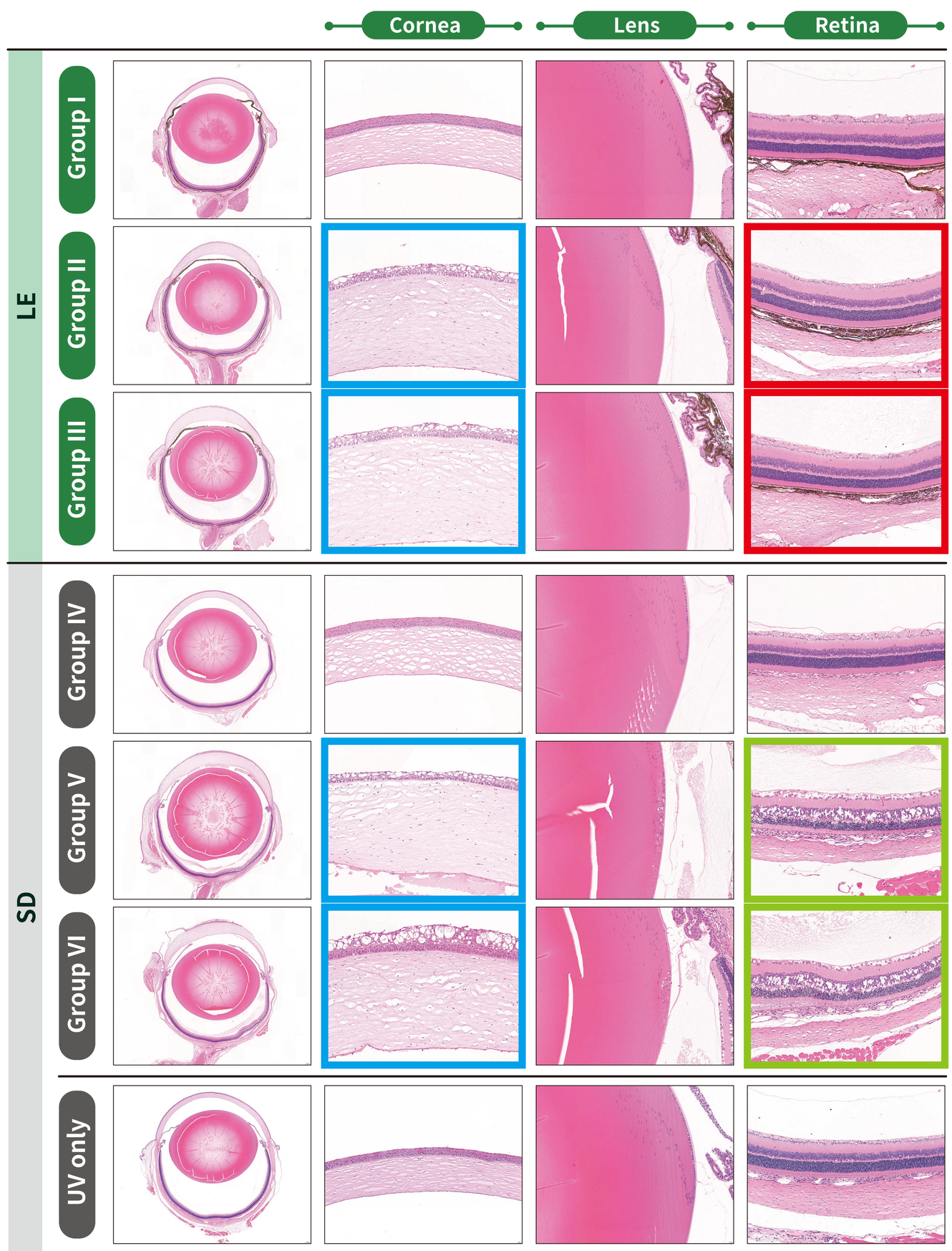

In LE rats, vacuolar degeneration/necrosis of the corneal epithelium and stromal edema were observed (Light blue square), whereas no apparent retinal changes were noted (Red square). No marked strain-related differences were observed in corneal lesions (Light blue square), while retinal lesions were observed only in SD rats (Light green square).